

Motion and deformation of the target volumes during IMRT for cervical cancer; what margins do we need?



University Medical Center
Utrecht

L. van de Bunt¹, I.M. Jürgenliemk-Schulz¹, G.A.P. de Kort², J.M. Roesink¹, J.H.A. Tersteeg¹, U.A. van der Heide¹
¹Department of Radiotherapy, ²Department of Radiology, University Medical Center Utrecht, The Netherlands

Introduction

For cervical cancer patients the clinical target volume (CTV) consists of multiple structures; the uterus, the cervix, the upper part of the vagina, parametria and the gross tumor volume (GTV). As these structures can move relative to each other, and change in volume, the changes in the encompassing CTV can be complex. The purpose of this study is to use weekly MR imaging to derive margins for the PTV that accommodate these changes.

Materials and Methods

Twenty patients with cervical cancer underwent a T2-weighted MRI exam before and weekly during IMRT. This resulted in five sets of images per patient. The CTV, GTV and surrounding organs were delineated. PTV margins were derived from the boundaries of the GTV and CTV in the anterior, posterior, right lateral, left lateral, superior and inferior direction and correlated with changes in the volumes of the bladder, rectum, sigmoid and bowel.

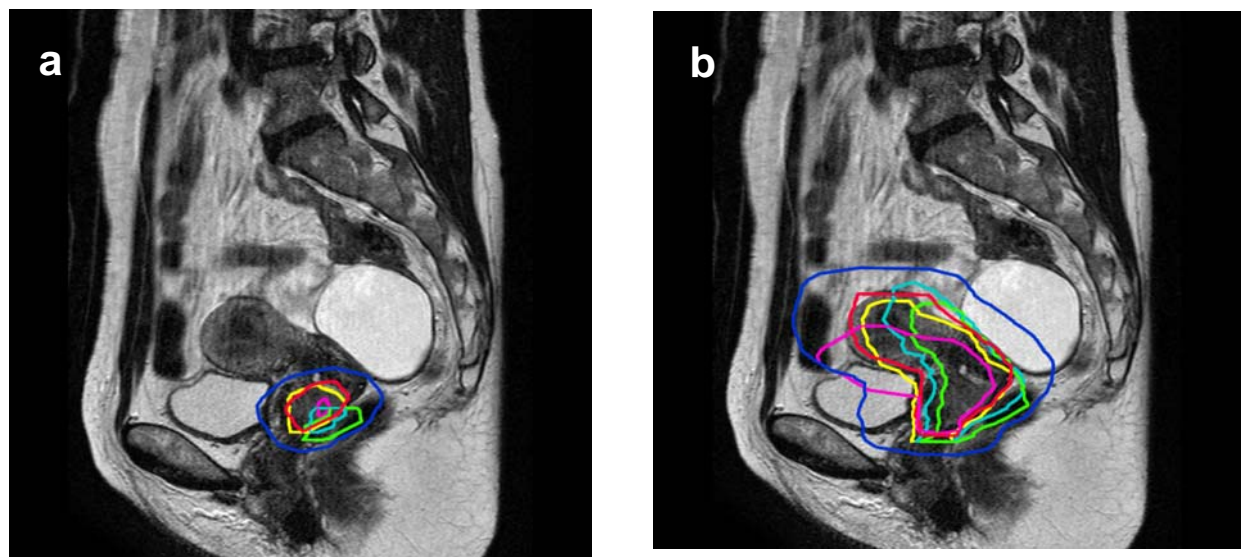
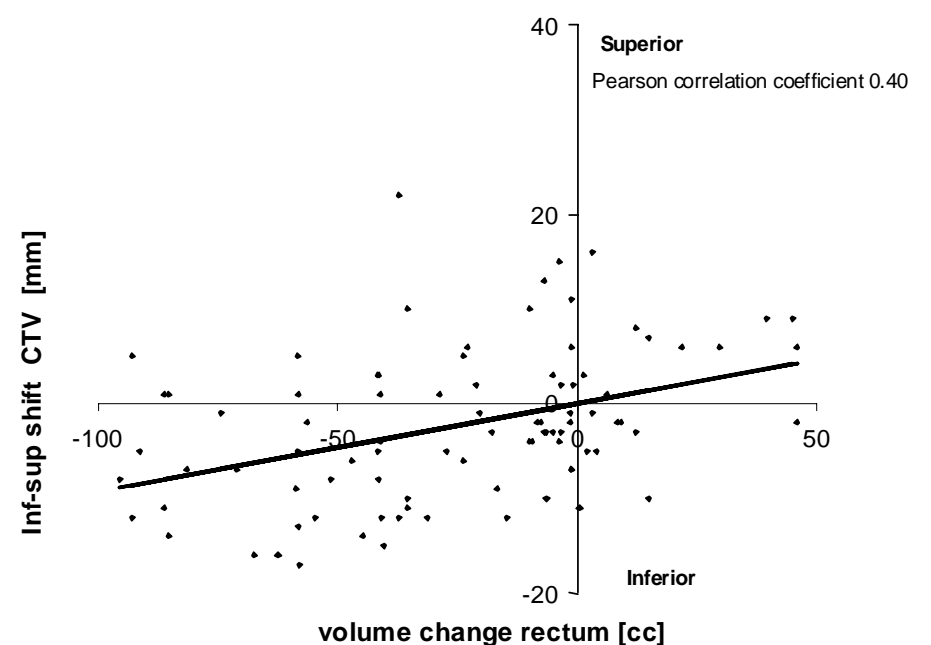
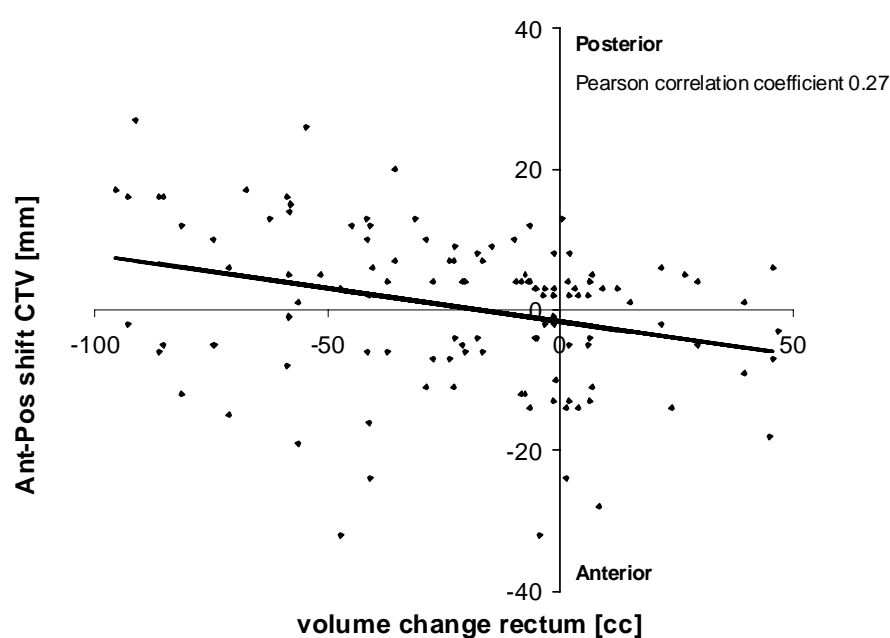


Figure 1a: The pre-treatment GTV (red) and four GTVs during IMRT (week 1 yellow, 2 light blue, 3 green, 4 magenta). The generic PTV is shown around the pre-treatment GTV (dark blue); 1b: analogous for the CTV.

Results

An inhomogeneous margin around the GTV of 12, 14, 12, 11, 4 and 8 mm to the anterior, posterior, right lateral, left lateral, superior and inferior direction was needed. Around the CTV even larger margins of 24, 17, 12, 16, 11 and 8 mm apply. The shift of the GTV in the ant-post direction, and CTV in the ant-post and inf-sup directions were weakly correlated with the change in rectum volume. For the bladder the correlations were even weaker.



Conclusion:

We used weekly MRI scans to derive inhomogeneous PTV margins around GTV and CTV for cervical cancer patients. The weak correlations with rectum and bladder volume during treatment suggest that measures to control filling status of these organs may not be very effective.