

# Comparison Of Megavoltage CT Image-Based Volumetric Dose Calculations With ICRU Reference Point Estimates Of Bladder And Rectal Doses During Low Doserate Intracavitary Brachytherapy For Cervical Cancer

T.H. Wagner, K.M. Langen, P.A. Kupelian, R.R. Manon, O.A. Zeidan, T.R. Willoughby, R.J. Staton, A.P. Shah, D. Buchholz, S.L. Meeks

MD Anderson Cancer Center Orlando

## Purpose

To present initial results of megavoltage computed tomography (MVCT) image-guided brachytherapy using a commercially available helical tomotherapy treatment unit and standard brachytherapy applicators used in low dose rate (LDR) brachytherapy for cervical carcinoma.

## Results

Significant differences exist between bladder and rectal 3D maximum doses and the respective ICRU point doses. ICRU bladder dose differs significantly from  $D_{BV2}$ . ICRU rectal dose does not differ significantly from  $D_{RV2}$ , and may be an acceptable surrogate for  $D_{RV2}$ .

## Materials and Methods

Spatial accuracy of MVCT image sets from the tomotherapy unit was verified by imaging a commercially-available stereotactic test phantom [1]. Dose calculation and point localization consistency was verified by a locally-built phantom [2,3]. Three dimensional (3D) dose distributions were computed and compared to two dimensional (2D) dose calculation results generated using digitally-reconstructed radiographs (DRRs) from the MVCT image sets [2,3]. Minimal doses received by the 2 cm<sup>3</sup> of bladder and rectum receiving the highest doses (DBV2 and DRV2, respectively) [4] were computed from dose-volume histograms and compared to the doses computed for the standard ICRU bladder and rectal reference dose points.

Between January 2005 to April 2006, ten patients at our institution received standard Fletcher-Suit GYN LDR brachytherapy (twenty implants) following 45 Gy pelvic irradiation at 1.8 Gy per fraction. For each patient, the two brachytherapy implants were planned to deliver an average point A dose of 80 Gy, without exceeding about 65 Gy total dose to the ICRU rectal dose point and 70 Gy to the bladder point. MVCT images and volumetric dose data were acquired for fifteen of the twenty implants during this time.

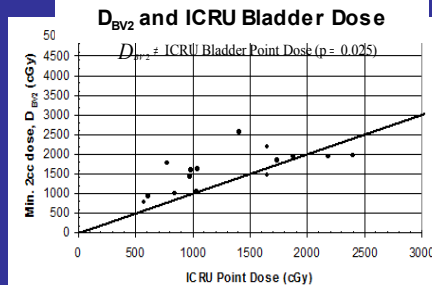
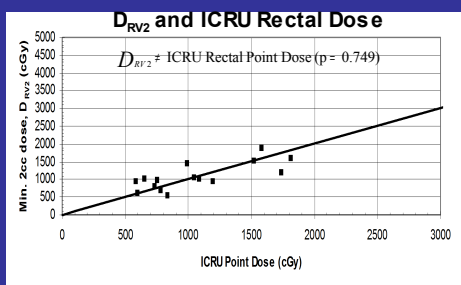


Figure 1 - Relationship between ICRU rectal and bladder reference point doses, and the minimum dose received by the highest-dosed rectum and bladder per DVH ( $D_{RV2}$  and  $D_{BV2}$ , respectively)<sup>4</sup>.

## Conclusion

Our initial experience in using MVCT imaging for clinical LDR gynecological brachytherapy indicates that the MVCT images are of sufficient quality for use in 3D, MVCT-based dosimetry. Helical tomotherapy MVCT imaging facilitates the use of 3D dosimetry for gynecological brachytherapy, without the need for CT-compatible brachytherapy applicators.

Table 1- Average and standard deviation of dose differences (Gy) between structure 3D maximum doses (from DVH) and ICRU reference points, and between 2cc doses and ICRU reference points for fifteen implants. P-values are for two-tailed paired-sample T-test.

	$\Delta_{3Dmax-bladder}$	$\Delta_{3Dmax-rectal\ pt}$	$\Delta_{DBV2-bladder}$	$\Delta_{DRV2-rectal\ pt}$
Avg. Diff. (Gy)	2.035	0.670	0.291	0.024
Std. Deviation	1.602	0.524	0.444	0.283
p	<0.001	<0.001	0.025	0.749

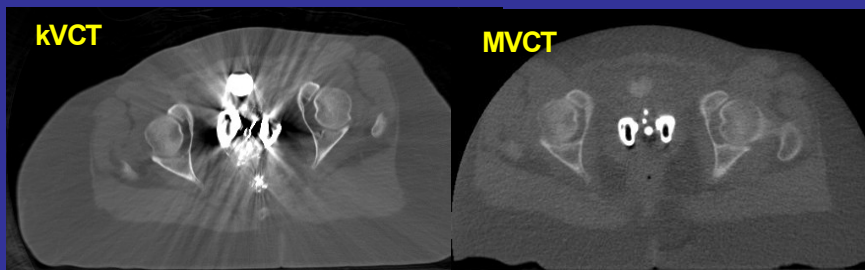


Figure 2 - (Left) Conventional CT (120 kVp) image of patient with standard Fletcher-Suit applicator implanted during 1<sup>st</sup> of two implants. (Right) Tomotherapy MVCT image of same patient and applicator during the second of two implants.

Table 2- Average volume (cm<sup>3</sup>) of bladder and rectum receiving at least the respective ICRU reference point dose.

Bladder	6.1 cm <sup>3</sup>
Rectum	2.0 cm <sup>3</sup>

## References

- Philips MH et al IJROBP 48(1):267-76, 2000.
- Wagner TH et al Med Phys 32(6): 1950, 2005.
- Wagner TH et al IJROBP 63(2):S338, 2005
- Pelloski CE et al IJROBP 62(1): 131-7, 2005.