

Frameless LINAC-based spinal radiosurgery results

Kevin Lin, M.D.†, Antonio A. F. De Salles, M.D., Ph.D.†, Alessandra G. Gorgulho, M.D.†, Nzhde Agazaryan, Ph.D.‡, John J. DeMarco, Ph.D.‡,

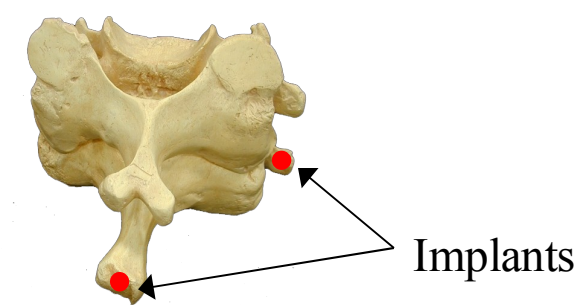
and Michael T. Selch, M.D.‡

†Department of Radiation Oncology, University of California, Los Angeles; ‡Division of Neurosurgery, University of California, Los Angeles

Introduction

The concept of delivering a focal ablative dose of ionizing irradiation is attractive for treatment of spinal column lesions and tumors in close proximity to the spinal cord (1). Spinal SRS utilizing invasive spinal column fixation, implanted bone fiducials (Figure 1) or specialized body frames with fiducial indicators has been reported by several groups (2-4).

Figure 1: Vertebra with implanted bone markers



Advances in infrared tracking, on-line portal visualization, and image fusion technology permit localization of a spinal column target acquired during computerized isodose planning at the isocenter of a linear accelerator with fidelity (5). Preliminary results of spinal RS using the non-invasive Novalis Body system have been reported by our group as well as others (6-7). The purpose of this study is to evaluate the safety and efficacy of spinal RS in a larger population.

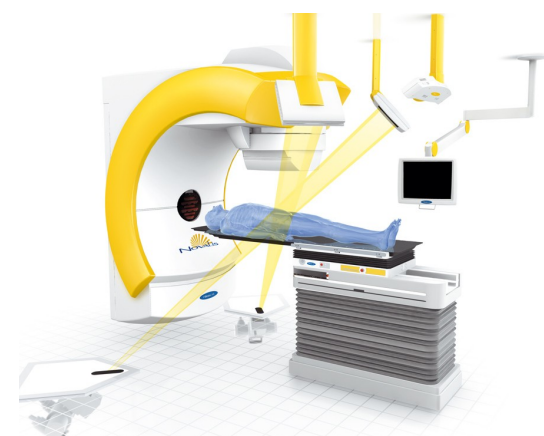
Materials and Methods

Patient Population

Forty-six patients with 65 lesions were treated at UCLA with single fraction spinal radiosurgery between January 2002 through October 2006. The mean peripheral dose was 12.2 ± 1.6 Gy (range 8–18 Gy) and the mean total dose was 13.5 ± 1.8 Gy (range 8.9–20 Gy) prescribed to the 90% isodose line (range 85–97%).

Four patients with metastatic lesions were lost to follow-up and nine new patients were treated within the last 6 months. Of the remaining 33 patients, the mean follow-up period was 13.8 ± 10.5 months (range 1–44 months). Follow-up consisted of imaging in 25 patients, and clinical follow-up in 33 patients. In cases where a clinic visit at UCLA was difficult due to distance or personal factors, phone follow-up was utilized to assess patient status.

Figure 2: Novalis X-ray positioning system



Radiosurgery Equipment

A Novalis Body for spinal radiosurgery was used (Figure 2). Five infrared passive reflectors attached noninvasively to the patient's skin were used for positioning of the target close to the isocenter of the LINAC. Radiographic image guidance was used for fine positioning adjustments based on internal anatomy (the spine). Infrared guidance is also used to monitor external patient motion during treatment.

Results

No complications due to spinal radiosurgery were noted. Figure 3 shows the results of the treatment, excluding those done within the last 6 months. Imaging follow-up was unavailable for 12 patients, due to patient death, loss to follow-up, or patient refusal. Figure 4 depicts the imaging results of the remaining treatments, excluding those performed in the last 6 months.

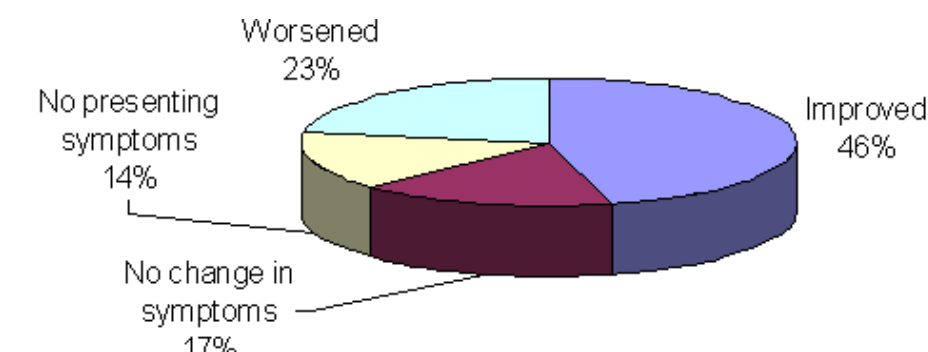


Figure 3: Overall clinical results

Of the benign cases, mean follow-up was 19 ± 12 months, excluding those patients treated within the last 6 months. Clinical results (Figure 5) and imaging results (Figure 6) illustrated below. Of note, no patients treated for benign lesions has had symptomatic or imaging progression of their lesions.

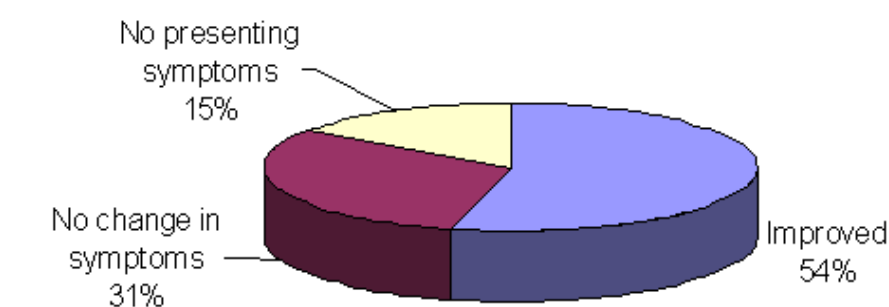


Figure 5: Clinical results (benign)

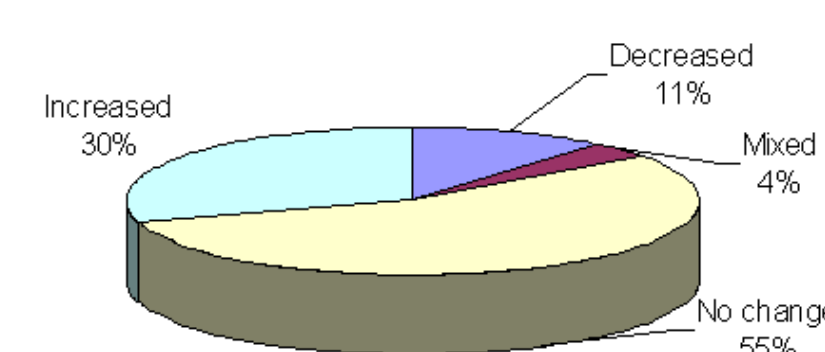


Figure 4: Overall imaging results

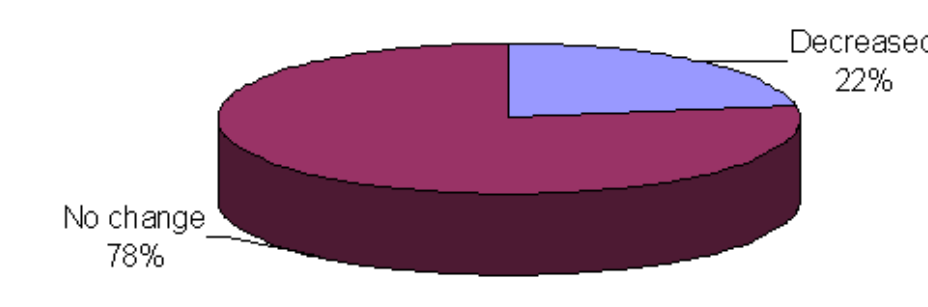


Figure 6: Imaging results (benign)

Discussion

Spinal radiosurgery can now be done without the use of implanted markers or fixed frames using various technologies. While much has been written about the use of CyberKnife systems, this study contributes to the body of evidence showing that LINAC based radiosurgery can also produce effective and durable results. One particular patient had breast cancer with an intramedullary metastasis in the L1 region, previously treated with 37.5 Gy. After 12 Gy of spinal radiosurgery, she had near complete resolution of this lesion (Figure 7).

Figure 7a: Patient with L1 lesion after 37.5 Gy

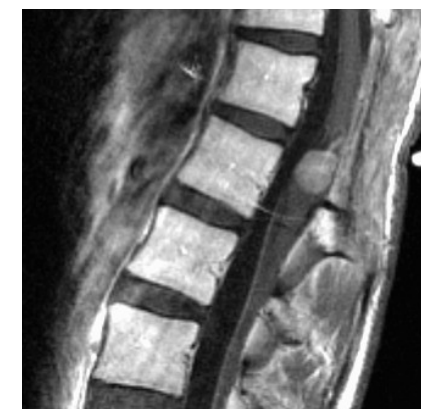
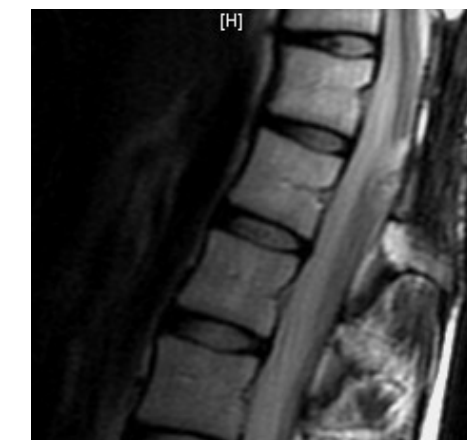
Figure 7b: After 12 Gy of spinal RS, near complete resolution.



In our series, no treatment failures or complications were noted with a mean follow-up of 19 months in patients treated for benign lesions. Though peri-operative neuromonitoring techniques allows for greater safe resection (8), surgery is still an invasive procedure with associated risks, especially for upper sacral tumors (9-10). Thus, radiosurgery should be considered as a primary treatment option for benign lesions, especially for sacral lesions or when multiple lesions of the spine are present, such as in neurofibromatosis patients.

Conclusions

Though technical immobilization difficulties previously limited the use of spinal radiosurgery, we, along with others, have shown that frameless radiosurgery on a linear accelerator is safe and effective with durable results. Additionally, for benign spinal tumors, radiosurgery shows the potential to be a modality that offers outstanding tumor control rates while reducing the need for more invasive and potentially more morbid surgical procedures.

Thus, radiosurgery represents a very effective and low risk alternative for patients with lesions of the spine, especially when the lesions are of benign pathology. Additional follow-up will further clarify the duration of treatment responses, and given the failure rate in metastatic lesions, further studies are still needed to examine the risk/benefit of dose escalation.

References

- [1] Rock JP, Ryu S, Yin FF, Schreiber F, Abdulhak M. The evolving role of stereotactic radiosurgery and stereotactic radiation therapy for patients with spine tumors. *J Neurooncol.* 2004 Aug-Sep;69(1-3):319-34.
- [2] Medin PM, Solberg TD, De Salles AA, et al. Investigations of a minimally invasive method for treatment of spinal malignancies with LINAC stereotactic radiation therapy: accuracy and animal studies. *Int J Radiat Oncol Biol Phys.* 2002 Mar 15;52(4):1111-22.
- [3] Hamilton AJ, Lulu BA, Fosmire H, et al. LINAC-based spinal stereotactic radiosurgery. *Stereotact Funct Neurosurg.* 1996;66(1-3):1-9.
- [4] Lohr F, Debus J, Frank C, et al. Noninvasive patient fixation for extracranial stereotactic radiotherapy. *Int J Radiat Oncol Biol Phys.* 1999 Sep 1;45(2):521-7.
- [5] Ryu S, Fang Yin F, et al. Image-guided and intensity-modulated radiosurgery for patients with spinal metastasis. *Cancer.* 2003 Apr 15;97(8):2013-8.
- [6] De Salles AA, Pedrosa AG, Medin P, et al. Spinal lesions treated with Novalis shaped beam intensity-modulated radiosurgery and stereotactic radiotherapy. *J Neurosurg.* 2004 Nov;101 Suppl 3:435-40.
- [7] Benzil DL, Saboori M, Mogilner AY, et al. Safety and efficacy of stereotactic radiosurgery for tumors of the spine. *J Neurosurg.* 2004 Nov;101 Suppl 3:413-8.
- [8] Quinones-Hinojosa A, Lyon R, Ames CP, et al. Neuromonitoring during surgery for metastatic tumors to the spine: intraoperative interpretation and management strategies. *Neurosurg Clin N Am.* 2004 Oct;15(4):537-47.
- [9] Fisher CG, Keynan O, Boyd MC, et al. The surgical management of primary tumors of the spine: initial results of an ongoing prospective cohort study. *Spine.* 2005 Aug 15;30(16):1899-908.
- [10] Mi C, Lu H, Liu H. Surgical excision of sacral tumors assisted by occluding the abdominal aorta with a balloon dilation catheter: a report of 3 cases. *Spine.* 2005 Oct 15;30(20):E614-6.

For further information

Please contact kelin@mednet.ucla.edu or call (310) 825-9771.

